ENDODONTIC CASE REPORT
HYBRIDIZING HEAT TREATMENTS TECHNIQUE
Prof.Gianluca Gambarini

A 42 year old female patient came to the office complaining about crown fracture and severe pain in the left mandibular posterior area. Intraoral and radiographic examination revealed disto-occlusal decay in tooth 3.6 (fig1), and exposure of the distal pulp horn. Tooth was highly sensitive to thermal cold test; an acute pulpitis was diagnosed and an endodontic orthograde treatment was proposed and accepted. Following a minimally invasive approach, access cavity was designed starting from the distal portion of the tooth, to avoid unnecessary loss of dentinal structure. Such a decision was a compromise between the advantages provided by a wider, straight line access (which is ideal in complex narrow curvature like in the present case) and the disadvantages from weakening the residual tooth structure: the mesial marginal ridge was intact, and it was decided to preserve it according to minimally invasive endodontic protocols. Moreover, an ideal straight-line insertion of endodontic nickel-titanium (NiTi) rotary instruments is not always possible when a molar is slightly distally inclined, like the present case. More complex root canal configurations (i.e. when additional canals are present like in this case) require more attention in planning adequate endodontic access to properly reach all the different orifices.

As a consequence, clinician was aware that NiTi rotary instruments would have been subjected to high flexural stress, due to the presence of multiple curvatures, which also required flexibility to be negotiated with no iatrogenic errors. Therefore, the first parameter was the selection of extremely flexible, heat treated, controlled-memory martensitic NiTi instruments; the second one was the selection of instruments with variable tapers to minimize taper-lock and screwing-in effect; the third parameter was the selection of instruments with enough metal mass to withstand torsional loads in narrow canals. The choice was in favor of EdgeTaper Platinum (ETP) by EdgeEndo, Albuquerque, NM, which provided all the required features; very resistant and flexible instruments, which can be deformed more easily than competitors' file and maintain the given precurvature, allowing an easier insertion and minimizing the need for a wider access cavity.

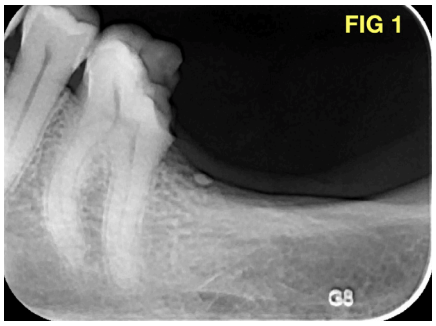

FIG 1

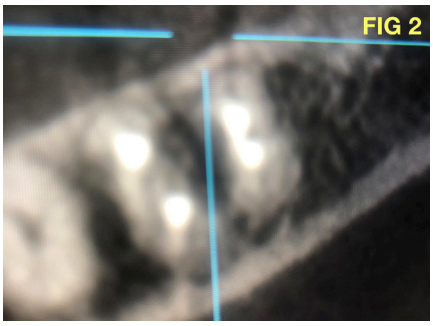
FIG 2

After a manual glide-path with stainless steel K-files up to size 15, and working length determination with an electronic apex locator, ETP instruments were used with the following sequence: S1, S2, F1, F2. All instruments reached the full working length, gently rotated at 300 rpm (and 2N torque), avoiding overloading. Two crucial operative parameters were chosen; first, during inward motion, instruments progressed slowly, in steps (not more than 1-2 mm progression for each step) and after each step they were removed from canals, the flutes were cleaned and syringe irrigation performed. Such a careful progression allowed to avoid excessive friction due to wider blade engagement and reduced debris inside the flutes. Moreover, debridement was enhanced with more frequent irrigation, and less production of debris.

The second parameter was the use of outward motion to improve coronal flaring. This could have been done with the same ETP instrument, but for the S1 and S2 instruments slightly more rigid EdgeTaper (ET) rotary instrument were chosen. ET instruments have same design of ETP but no heat treatment, which makes them a bit more stiff and efficient in cutting. Therefore, ET S1 and S2 (used after ETP S1 and S2, respectively) allowed a more rapid and valid coronal flaring. They were used only with an outward motion ("brushing"), an increased speed (500 rpm) and reduced torque (1.5N). By eliminating coronal interferences and increasing canal diameters ET S1 and S2 made apical preparation with ETP F1 and F2 quicker and safer, as shown in the CBCT images (fig 2 and 3). Outward motion was found to be extremely safe, with minimal torsional and flexural loads on the NiTi rotary instruments, provided that the instruments are never fully engaged or blocked inside canal. This new, innovative combination of similar instruments (ET and ETP) with different properties related to a different manufacturing process, is called "hybridizing heat-treatments technique" and was nicely performed using the above-mentioned instruments. Fig 3 and 4 show how canal trajectories were nicely maintained, and proper shaping (adequate canal diameters can be better appreciated in 3D images, as shown by figures 2 and 3) was quickly and simply performed in a 45-minute single-visit root canal treatment, with no iatrogenic errors, no instruments' deformation or fracture. Canals were obturated with a single cone cold hydraulic technique using Bioceramic Sealer (BC Sealer, BUSA, USA), a material that provides a simple and fast solution.


FIG 3

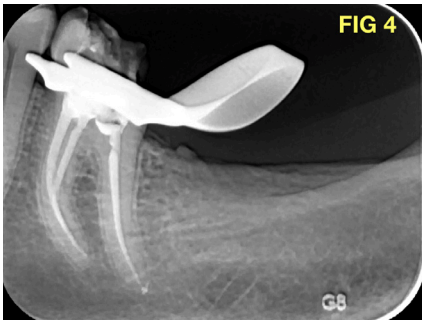

FIG 4